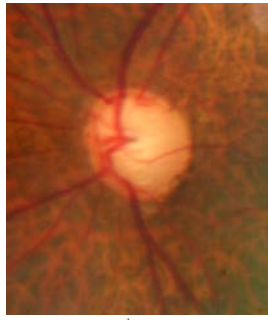


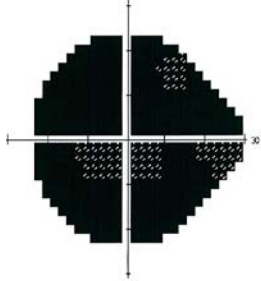
**Patient A.**

Disc Photo

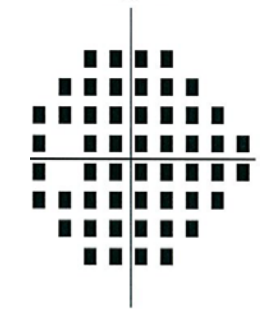


Visual Field:

Grey Scale



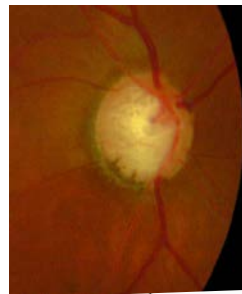
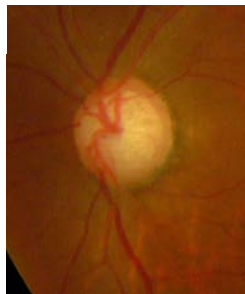Pattern Defect



Imaging and testing of right eye not possible due to corneal oedema from rubeotic glaucoma subsequent to a central retinal vein occlusion, which occurred after initial diagnosis.

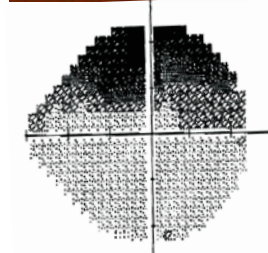

**Patient B.**

Disc Photo

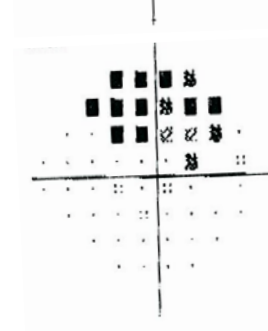
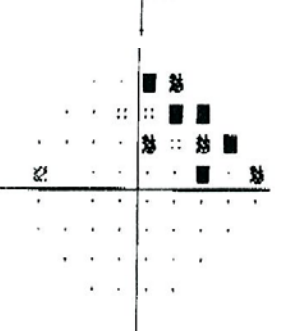


Visual Field:

Grey Scale



Pattern Defect



**LEFT**

**RIGHT**

Figure 3.